

Intervertebral Disc Repair by Autologous Mesenchymal Bone Marrow Cells: A Pilot Study

Lluís Orozco,¹ Robert Soler,¹ Carles Morera,² Mercedes Alberca,³ Ana Sánchez,³ and Javier García-Sancho^{3,4}

Background. Degenerative disc disease may cause severe low-back pain, a large public health problem with significant economic and life quality impact. Chronic cases often require surgery, which may lead to biomechanical problems and accelerated degeneration of the adjacent segments. Cell-based therapies may circumvent these problems and have exhibited encouraging results in vitro and in animal studies. We designed a pilot study to assess feasibility and safety and to obtain early indications on efficacy of treatment with mesenchymal stem cells (MSC) in humans.

Methods. Ten patients with chronic back pain diagnosed with lumbar disc degeneration with intact annulus fibrosus were treated with autologous expanded bone marrow MSC injected into the nucleus pulposus area. Clinical evolution was followed for 1 year and included evaluation of back pain, disability, and quality of life. Magnetic resonance imaging measurements of disc height and fluid content were also performed.

Results. Feasibility and safety were confirmed and strong indications of clinical efficacy identified. Patients exhibited rapid improvement of pain and disability (85% of maximum in 3 months) that approached 71% of optimal efficacy. This outcome compares favorably with the results of other procedures such as spinal fusion or total disc replacement. Although disc height was not recovered, water content was significantly elevated at 12 months.

Conclusions. MSC therapy may be a valid alternative treatment for chronic back pain caused by degenerative disc disease. Advantages over current gold standards include simpler and more conservative intervention without surgery, preservation of normal biomechanics, and same or better pain relief.

Keywords: Back pain, Intervertebral disc, Nucleus pulposus, Mesenchymal stem cells, Stem cell therapy.

(*Transplantation* 2011;92: 822–828)

Intervertebral disc degeneration is a common disease that can lead to axial skeletal pain, radiculopathy, and myelopathy. Combined physical and medical therapies are successful in relieving pain in approximately 90% of the cases. However, the remaining 10% become chronic and generate a serious public health problem, as chronic low-back pain (CLBP) ru-

ins both the life quality and the labor capacity of the patient and increases the use of health services (1, 2).

Physical therapy and exercise are generally the first choice for treatment of CLBP. When these fail, several types of surgery are performed to relieve pain and decrease disability. The most common interventions are spinal fusion (arthrodesis) with damaged disc removal (discectomy) or substitution by artificial materials (arthroplasty; total disc replacement). The indication of surgery in CLBP is controversial because of its side effects, disturbance of motion and other biomechanical consequences that can accelerate the degenerative cascade at the operative level and at adjacent segments (3, 4). Despite of these risks, spinal fusion is the gold standard for CLBP (1, 5) and its analgesic value is beyond question. Figure 1 presents an extensive meta-analysis of seven high-quality recent clinical trials. Data on evolution of pain and disability were recalculated and expressed on a 0% to 100% scale. Quantification and comparison of several CLBP treatments was performed using

This work was supported by the Advanced Therapies Program of the Spanish Ministerio de Sanidad, the Red de Terapia Celular grant RD06/0010/0000 of the Instituto de Salud Carlos III, Ministerio de Ciencia e Innovación, and the Centro en Red de Medicina Regenerativa de Castilla y León.

The authors declare no conflicts of interest.

¹ Institut de Teràpia Regenerativa Tissular (ITRT), Centro Médico Teknon, Barcelona, Spain.

² Spinal Surgery Unit, EGARSAT, Terrassa, Spain.

³ Instituto de Biología y Genética Molecular (IBGM), University of Valladolid and CSIC, Valladolid, Spain.

⁴ Address correspondence to: Javier García-Sancho, M.D., Ph.D., Instituto de Biología y Genética Molecular (IBGM), c/Sanz y Fores, 3, 47003 Valladolid, Spain.

E-mail: jgsancho@ibgm.uva.es

J.G.S. had full access to all of the data in the study and takes responsibility for the integrity of the data and the accuracy of the data analysis. L.O., R.S., A.S., and J.G.S. participated in the conception and design of the article. L.O., R.S., and C.M. were primarily responsible for the clinical work, and A.S. and M.A. for the cell production. All authors participated in analysis, discussion and interpretation of data, revision of the article, and gave final approval of the version to be published. J.G.S. put together all data, did meta-analysis, and wrote the final form of the manuscript.

Supplemental digital content (SDC) is available for this article. Direct URL citations appear in the printed text, and links to the digital files are provided in the HTML text of this article on the journal's Web site (www.transplantjournal.com).

Received 18 April 2011. Revision requested 23 May 2011.

Accepted 13 June 2011.

Copyright © 2011 by Lippincott Williams & Wilkins

ISSN 0041-1337/11/9207-822

DOI: 10.1097/TP.0b013e3182298a15

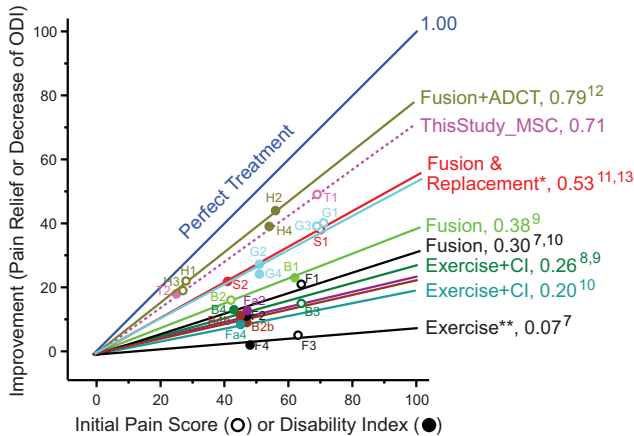


FIGURE 1. Comparison of the efficacy of several treatments of chronic low-back pain for pain and disability relief. Data from seven clinical trials (7–13), quantified using Visual Analog Scale (open circles) and Oswestry Disability Index (ODI; filled circles) are represented as pain relief vs. initial pain score (6). The slope of the lines (values at right) represents efficacy. Lines were forced to pass through the origin. The data from the present study (This Study_MSC) are also included for comparison. ADCT, autologous disc cell transplantation. CI, cognitive intervention. *Replacement with ProDisc and Charite prostheses (with fusion) or fusion only; slope range from 0.50 to 0.56. **This group was somewhat inhomogeneous because some subgroups received different cognitive interventions. For a more detailed description, letter codes, and numerical values see Supplemental Table (SDC 1, <http://links.lww.com/TP/A475>).

the initial pain score versus pain relief plot (6) (for more details, see Table, SDC 1, <http://links.lww.com/TP/A475>).

The slope of the line defines the efficacy of any particular treatment, with complete pain relief attaining a slope of 1 (Fig. 1). The changes in pain scores (open symbols) and Oswestry Disability Indexes (ODI, closed symbols) can be plotted together, as the same relationship between the variables exists. Exercise, the conventional “nonsurgical” treatment (7), was the least potent treatment, with an efficacy of 0.07. The efficacy of treatments involving cognitive intervention plus exercise (8–10) ranged between 0.20 and 0.29, and spine fusion protocols were the most effective, with an efficacy ranging between 0.30 and 0.71 in different trials (7, 9–12). Disc replacement protocols with artificial discs had the same efficacy as fusion alone (11, 13). Finally, one trial (12) compared the effects of discectomy with discectomy plus treatment with cells expanded from the excised disc material (autologous disc cell transplantation in Fig. 1). A small but significant improvement was found in the group supplemented with cells after 2 years (see Table, SDC 1, <http://links.lww.com/TP/A475>) (12). However, a group with only cells was not included and thus, the effectiveness of these expanded cells alone is not yet known.

Progress in the understanding of degenerative disc disease pathophysiology has promoted study of new biologic therapies, including cell-based strategies. Potential advantages of these treatments are preservation of normal surrounding anatomy, biomechanics, and motion. Cell therapy has produced exciting results in both in vitro and in vivo (14),

and studies with mesenchymal stem cells (MSC) have been particularly promising. Co-culture of MSC with nucleus pulposus cells stimulates both nucleus pulposus cells proliferation and MSC differentiation toward the chondrogenic lineage (15–18). Increased production of cytokines, particularly transforming growth factor-beta favors these transformations (18–20). The nucleus pulposus contains MSC that are similar to the MSC recovered from bone marrow (21), and studies in animal models of disc degeneration have shown that MSC injected in the nucleus pulposus area not only survive for months but also proliferate in canine (12, 22), porcine (23), and rabbit models (24). In addition, transplanted MSC induced production of extracellular matrix proteins, including aggrecan and other proteoglycans, and types I and II collagens (12, 23, 24). Finally, these studies also reported that injection of MSC resulted in better preservation of height and water content of the disc (12, 22, 25). Although animal data are very promising, MSC-based therapies have not yet been tested in humans. The only reported study involving treatment of CLBP with stem cells was carried out with unexpanded bone marrow hematopoietic precursors and no improvement of the pain was reported (26).

Based on the results of previous in vitro and animal experiments, we conducted a pilot study to test feasibility and safety and to obtain an early indication of the therapeutic value of MSC in human patients with chronic degenerative disc disease. Using autologous bone marrow Good Manufacturing Practice (GMP)-compliant MSC maximizes biosecurity of the protocol because of the previous experience with bone marrow transplantations. Furthermore, the intervention proposed here does not require surgery, does not produce anatomical modifications and does not hinder further interventions should they be required.

RESULTS

Patients

This pilot study included 10 patients (4 male and 6 female; average age 35 ± 7 years) diagnosed of degenerative disc disease with preserved external annulus fibrous and persistent low-back pain. Additionally, all 10 patients did not respond to conservative treatment (physical and medical) lasting at least 6 months. Details on inclusion and exclusion criteria are presented in Supplemental Table 2 (see SDC 2, <http://links.lww.com/TP/A476>). The lesion was located at L4-L5 (2), L5-S1 (6), or both discs (2). Patients were recruited between June and December 2008 and treated from December 2008 to June of 2009. No major adverse events occurred.

Cell Expansion

The cell parameters were as follows (mean \pm standard deviation [SD]; $n=10$): bone marrow volume, 89 ± 5 mL; total number of mononuclear cells obtained, $794 \pm 345 \times 10^6$; expansion time, 24 ± 4 days; number of passages, 3; number of MSC released, $23 \pm 5 \times 10^6$; viability at the time of release, $87\% \pm 6\%$; viability at the time of application, $83\% \pm 5\%$. Expansion was performed under GMP conditions, with progression being monitored every other day. After 7 to 10 days in culture, cells became relatively homogeneous and had a fibroblastic appearance when approaching confluence. This morphology remained unchanged until release of cells for

TABLE 1. Total sumscore of Visual Analogue Scale measurements for lumbar and sciatic pain and Oswestry Disability Index

Test	Time	N	Mean	SE	Min	P25% ^a	P50% ^a	P75% ^a	Max
Lumbar pain (Visual Analogue Scale; 0–100)	0	10	68.9	3.3	44.0	69.0	70.0	74.0	82.0
	3 mo	10	26.5	5.6	3.0	15.0	25.0	43.5	50.0
	6 mo	10	21.6	6.0	3.0	6.5	17.0	28.5	63.0
	12 mo	10	20.0	6.5	5.0	9.3	14.0	19.5	75.0
Sciatic pain (Visual Analogue Scale; 0–100)	0	6	37.0	9.3	21.0	22.8	36.0	71.0	100.0
	3 mo	6	24.3	12.6	0.0	6.3	26.0	42.8	79.0
	6 mo	6	7.8	6.9	0.0	0.5	2.5	38.3	80.0
	12 mo	6	5.3	5.1	0.0	0.5	2.5	38.3	80.0
Oswestry Disability Index; (0–100)	0	10	25.0	4.1	6.0	22.0	25.0	29.5	50.0
	3 mo	10	13.0	3.2	2.0	5.5	11.0	17.0	36.0
	6 mo	10	9.4	2.7	0.0	2.0	7.0	15.5	26.0
	12 mo	10	7.4	2.3	0.0	2.0	5.0	9.5	22.0

In all the cases, the scale was from 0% to 100%. Measurements were performed before cell transplantation (0) and 3, 6, and 12 mo later. In the case of sciatic pain, four patients showing not such pain at the beginning of the treatment were excluded from the statistics.

^a P25%, P50%, and P75% stands for percentile 25%, 50% (median), and 75%, respectively.

SE, standard error; Min, minimum value; Max, maximum value.

treatment (see **Figure, SDC 3**, <http://links.lww.com/TP/A477>). The antigenic profile conformed to the International Society for Cellular Therapy criteria for MSC (27) (see **Figure, SDC 4**, <http://links.lww.com/TP/A478>).

Evolution of Pain, Disability, and Life Quality

Table 1 summarizes the distribution of pain and disability indexes throughout the observation period. The starting point of pain and disability in the cohort was homogeneous. Patients on average felt intense lumbar pain (69 ± 3 in the Visual Analog Scale [VAS]) and had moderate disability (ODI of 25 ± 4) (mean \pm standard error [SE]; $n=10$). Six of the patients had sciatic pain at the beginning of the trial, and their evolution is also included in Table 1. On average, both lumbar pain and disability were strongly reduced at 3 months after MSC transplantation, followed by modest additional improvement at 6 and 12 months (Fig. 2A, B). Compared with the basal level of pain and disability, improvement was statistically significant at all time points (Fig. 2 legend). The sciatic pain followed the same trend, but the variation with respect to pain and disability among the patients was larger (Fig. 2C). The improvement in sciatic pain was significant at 6 and 12 months compared with the beginning of the trial. The pattern of improvement between VAS and ODI was parallel and resulted in global displacement of the whole distribution towards smaller values, with a strong decrease of the medians (P50% in Table 1). The improvements in pain and ODI at 12 months demonstrated a strong positive correlation with the values attained at 3 months (Fig. 2D; $r=0.79$; $P<0.0001$). The slope of the line was 1.17, indicating that the healing effect of MSC was rapid. In fact, 85% of the total improvement occurred during the first 3 months.

In Figure 3, we have plotted lumbar pain relief, assessed by VAS, at the end of the treatment as a function of the initial pain score (6) (Fig. 3; inverted triangles). The efficacy of the treatment is equal to the slope of the dotted line, which we compared to the “perfect treatment” with a slope of 1 (continuous line). The evolution of the disability index (circles)

was plotted together with VAS-assessed values (inverted triangles) and exhibited the same relationship. Evolution of sciatic pain in the six affected patients was also followed (triangles). There was an excellent positive correlation between the initial score and the amount of improvement ($r=0.78$), indicating that the MSC treatment had a clear pain-relieving and disability-healing effect ($P<0.0001$). Regression analysis also resulted in a significant slope ($P<0.0001$). The slope of the line, which defines the efficacy of the treatment (6), was as high as 0.71, indicating that the effectiveness of MSC treatment is considerable. The results were consistently good for nine of the patients, but patient 3 (P3 in Fig. 3) did not demonstrate any apparent benefit from treatment.

The short form-36 (SF-36) life quality questionnaire revealed, by the end of treatment, a significant improvement of the physical component (summary value from 12.7 ± 3.7 to 24.8 ± 3.9 ; mean \pm SE; $n=10$; $P<0.05$) with no change of the mental component (from 54.1 ± 10.6 to 49.7 ± 10.5 ; $P=0.77$).

Imaging

Magnetic resonance imaging (MRI) was used to assess disc height and water content of the discs. The heights of the affected disc segments were (in mm; mean \pm SE; $n=10$): 9.86 ± 0.57 , 9.81 ± 0.55 , and 9.84 ± 0.63 at 0, 6, and 12 months of transplantation, respectively. These values were not significantly different. Water content of the discs, determined from T2-weighted sagittal images, was measured in the affected disc segment and in the contiguous 3 to 5 segments above the affected segment (see **Figure, SDC 5**, <http://links.lww.com/TP/A479> and **Methods, SDC 6**, <http://links.lww.com/TP/A480>). A summary of the analysis of fluid content is shown in Table 2 and individual results are detailed in Supplemental Figure 3D (see **SDC 5**, <http://links.lww.com/TP/A479>). The water content values for the affected disc are normalized by the values from the healthy discs in the same individual, which created a ratio. The ratio of fluid content of the affected segments to healthy segments was low at the beginning of treat-

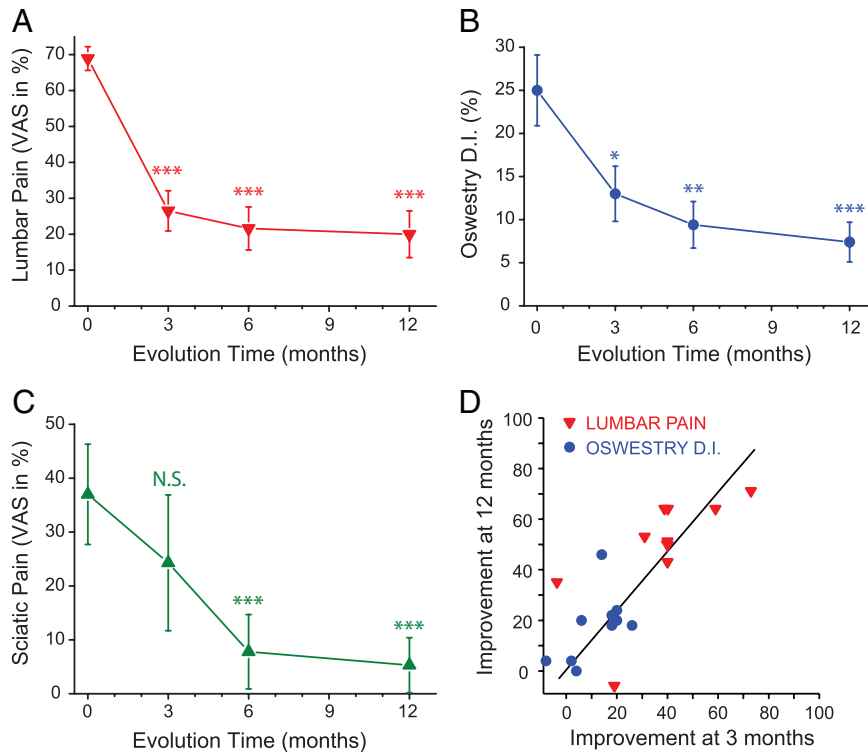


FIGURE 2. Temporal evolution of pain and disability over time after mesenchymal stem cells (MSC) treatment. (A) Graph showing lumbar pain over time. Differences between 3 and 6 months or between 3 and 12 months were not statistically significant. VAS, Visual Analog Scale. (B) Graph showing disability over time as measured by Oswestry Disability Index (ODI). Differences between 3 and 6 months or between 3 and 12 months were not statistically significant. (C) Graph showing sciatic pain over time (only six patients that showed sciatic pain at the time of the intervention were analyzed). Differences between 3 and 6 months and 3 and 12 months were statistically significant ($P < 0.05$). Means \pm standard error are shown. Data were analyzed using analysis of variance, paired populations, Bonferroni test. Comparisons with $t=0$: N.S., nonsignificant, $*P < 0.05$; $**P < 0.01$; $***P < 0.001$. (D) Correlation between improvement of lumbar pain (inverted triangles) and disability index (circles) at 3 and 12 months after MSC treatment. The line fitting all the 20 data ($Y = 1.17X$) is shown. Linear regression analysis: $r = 0.79$; $P < 0.0001$.

ment (mean \pm SE; $n = 11$) at 0.62 ± 0.03 . This value did not change significantly at 6 months but increased to 0.72 ± 0.03 at 12 months, a difference that was statistically significant ($P < 0.05$, ANOVA; Bonferroni test; $P = 0.03$, paired t test, two-tailed value).

DISCUSSION

Previous results from in vitro and animal studies indicated that using expanded bone marrow MSC to treat degenerative disc disease may be effective (14). This study, to the best of our knowledge, is the first to investigate this cell therapy in humans. Our results show that autologous MSC transplantation is both feasible and safe, with no major adverse effects recorded. The subjective evolution was favorable, and 9 of the 10 patients improved. The GMP-compliant cell preparation was satisfactory and production was reproducible with respect to number of cells ($SD = 22\%$) and expansion time ($SD = 17\%$). Immunophenotypic characteristics were also adequate and stable over time (see **Figure, SDC 4**, <http://links.lww.com/TP/A478>). Cell viability was good and not affected by transport to the site of administration or passage through spinal needles (data not shown). Quality control tests, including karyotype monitoring in three cell lots, were also satisfactory.

The analgesic effect of treatment with MSC was remarkable, approaching 71% efficacy. The improvement in pain was accompanied by a parallel improvement in disability (Fig. 3) and physical life quality (SF-36 results). In Figure 1, we have compared our results with the outcomes of previous clinical trials investigating other therapeutic interventions. Our results, labeled "This Study_MSC" in Figure 1, compare favorably with previous trials that explored physical treatments (7–10), and spinal fusion with or without disc replacement (7, 9–12) or complemented with expanded disc material (12). The analgesic effect of the intervention described here was rapid, as most of the improvement in pain (85%) was attained by 3 months (Fig. 2). Early action has also been reported for surgical interventions (12, 13).

In previous studies, no recovery of disc height has been reported 5 years after spinal fusion with or without total disc replacement (11) or 2 years after discectomy or discectomy plus cell treatment with cells expanded from the excised material (12). In the present study, we also found no improvement in disc height. However, the fluid content of the affected disc segments was significantly elevated at 1 year after the intervention (Table 2; see **Figure, SDC 5**, <http://links.lww.com/TP/A479>). This is consistent with the results obtained in animals, in which MSC were

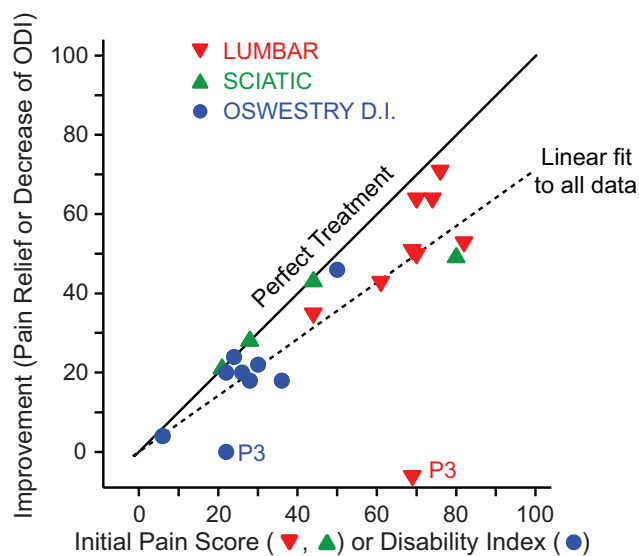


FIGURE 3. Pain and disability improvement as a result of mesenchymal stem cell treatment. Level of improvement is plotted as a function of the initial pain score value or disability index (6). Results for the relief of lumbar pain (*inverted triangles*), sciatic pain (*triangles*), and Oswestry Disability Index (ODI; *circles*) are all included. The continuous line with slope 1 represents the perfect treatment, in which complete pain or disability relief was achieved. The dotted line corresponds to the linear fit of all data. The values of the best fit ($n=26$; linear regression forced through the origin) were as follows: slope, 0.71; $P<0.0001$; Correlation analysis, Pearson $r=0.78$; $P<0.0001$. P3 stands for patient 3.

TABLE 2. Fluid contents of the discs along the trial period

	Density ^a before transplantation	Density ^a 6 mo afterward	Density ^a 12 mo afterward
Mean	0.62	0.63	0.72 ^b
Standard error	0.03	0.03	0.04
n	11	11	11

^a Image densities were measured in the T2-weighted MRI images and are normalized to 1 with regard to the healthy discs (see Figure, SDC 5, <http://links.lww.com/TP/A479>).

^b Comparison with control before transplantation: analysis of variance, Bonferroni test; $P<0.05$; paired t test, $P=0.03$ (two tailed).

able to stop progression of disc dehydration and even induced water gain (22, 25). Injection of the excipient without cells had no effect (25). A slight increase of water content has also been reported in patients treated with surgery plus cells expanded from the excised disc, although this increase was seen only at 2 years after the intervention (12). We shall certainly follow the evolution of pain, disability, disc height, and disc water content in our patients in next year.

We can only speculate regarding the mechanism by which the beneficial effect of this treatment occurs. Animal

studies have shown that MSC injected in the NP area are able to survive and proliferate (23, 24) and induce beneficial effects in degenerative disc disease (22, 25). Nucleus pulposus cells induce differentiation of co-cultured MSC into nucleus pulposus-like cells with a chondrocyte phenotype (15, 16, 19) and, even more importantly, MSC stimulated nucleus pulposus cells to proliferate and synthesize extracellular matrix (17, 18). This action may be important in vivo as few MSC are required to trigger this effect (18). In addition, MSC have a well-known immunomodulatory effect and express Fas-ligand when implanted in the spinal discs of dogs (22). These data indicate that MSC may help analgesia by reducing inflammation. Additionally, MSC can induce the production of anti-inflammatory cytokines (18). Because the analgesic effect is more evident than anatomical restoration, we may conclude that the trophic effects are faster than the regenerative ones, at least within 1 year after treatment. Note that, because of the potential systemic immune suppression and stromal support by MSC, concerns remain about possible facilitation of systemic infections and tumor growth. Long-term follow-up studies are required to address these issues (28).

Arthrodesis and arthroplasty restrict mobility and lead often to adjacent segment degeneration (1, 3). A continual decrease in disc height has been reported even after intervertebral disc transplantation (29). The alternative cell-based therapy proposed here avoids these side effects and is a simpler, less-invasive intervention. MSC treatment does not require surgery, and can be performed under an ambulatory regime. The cell treatment is expensive today, principally because cell production must be performed under astringent GMP conditions. However, the costs should decrease substantially in future as a result of larger scale production and more feasible regulation.

In summary, we propose that cell therapy with expanded bone marrow-derived mesenchymal cells should be considered as a putative treatment of chronic back pain caused by disc degeneration. Cell handling and expansion is reproducible and quality control tests were satisfactory. The clinical procedure is feasible and safe, and has several advantages over the current gold standard treatments: the intervention is simpler, more conservative, preserves normal biomechanics, does not require surgery or patient hospitalization, and results in the same or better pain relief. Future studies will involve larger trials centered in efficacy, with increased patient number and longer follow-up period. These studies will track the long-term evolution and investigate the anatomical and functional changes that occur in the intervertebral spaces. The possibility of cryopreserving a part of the harvested cells for subsequent multi-dose application would be extremely interesting to explore.

MATERIALS AND METHODS

Patients and Procedures

This study was designed as a pilot phase I trial. The protocol was approved first by the Teknon Medical Centre Ethics Committee and then by the Spanish Drug and Medicines Agency (EudraCT 2008-001191-68). Ten patients with chronic lumbar pain and positively diagnosed with lumbar disc degeneration and intact annulus fibrosus demonstrated by discography (30, 31) were included. Details on the inclusion and exclusion criteria are reported in Supplemental Table 2 (see Table, SDC2,

<http://links.lww.com/TP/A476>). After complementary clinical, analytical, and imaging explorations to secure compliance with these criteria, the patient was informed about the characteristics of the protocol and, if he agreed to participate, he was asked to sign the informed consent.

The protocol included seven visits (V0–V6) with the following contents: V0, final check of compliance with I/E criteria, performance of all the needed complementary explorations and tests, programming of dates for V1 and V2; V1, bone marrow harvesting from the iliac crest (80–90 mL) for preparation of MSC. The patient was discharged after a 2-hr observation period. This intervention was performed under local anesthesia and slight sedation; V2 (3–4 weeks after V1), injection of MSC ($10 \pm 5 \times 10^6$ cells per disc from a suspension containing 10^7 cells/mL) in the nucleus pulposus area of the affected segment (for details, see **Methods**, **SDC 6**, <http://links.lww.com/TP/A480>). V3–V6, are visits at 8 days, and 3, 6, and 12 months after implantation, which included clinical exploration and routine analysis (V3–V6), VAS, ODI, and SF-36 questionnaire, and quantitative MRI exploration (V5 and V6).

Cell Isolation and Expansion

Cell isolation and expansion were performed in the IBGM Cell Production Unit under GMP conditions and with specific approval of the Spanish Drug and Medicines Agency. The bone marrow sample was transported to the Cell Production Unit at 4 to 12°C within 12 hr of harvesting. The mononuclear cell fraction was isolated by density-gradient centrifugation, resuspended and cultured in the MSC expansion culture medium (21) in 175 cm² tissue culture flasks with periodical washing to remove nonadherent cells. When cells reached 80% confluence they were trypsinized and replated, and the process was repeated for two more passages. At the end of this period (21–28 days), cells were harvested, resuspended in Ringer-lactate solution containing 0.5% human albumin (clinical grade, CSL Bhering GmbH, Marburg, Germany) and 5 mM glucose, and transported at 4 to 12°C by air courier (6 hr) to Teknon Medical Centre for application. In addition to quality control tests, viability and flow cytometric immunophenotypic profile (21, 27) were also determined at this stage.

Follow-Up Controls

In addition to the standard clinical and analytical procedures, the follow-up visits included measuring lumbar pain with VAS (6), disability with ODI, and life quality with SF-36 questionnaire (32). Results are expressed on a 0% to 100% scale in all the cases. MRI was used to measure disc height (22, 24) and to assess disc fluid content in T2-weighted sagittal images (see **Figure**, **SDC 5**, <http://links.lww.com/TP/A479>) (22, 25, 33).

Statistical Analysis

Data are reported as mean \pm SD or SE, as indicated in each case. Significant differences were assessed using GraphPad Instat3 package software, GraphPad Software, La Jolla, CA.

ACKNOWLEDGMENTS

The authors thank Mr. Jesús Fernández and Ms. Carmen Barbero for technical support. They also thank Dr. J.J. Velazquez, Traumatology Service, EGARSAT (Traumatology consultant), Dr. Andy Leist, Centro Médico Teknon (MRI), and Prof. J. Sentís, Department of Public Health, Medical School, University of Barcelona (advise with statistics).

REFERENCES

- Errico TJ, Gatchel RJ, Schofferman J, et al. A fair and balanced view of spine fusion surgery. *Spine J* 2004; 4: S129.
- Balague F, Mannion AF, Pellise F, et al. Clinical update: Low back pain. *Lancet* 2007; 369: 726.
- Harrop JS, Youssef JA, Maltenfort M, et al. Lumbar adjacent segment degeneration and disease after arthrodesis and total disc arthroplasty. *Spine* 2008; 33: 1701.
- Rihn JA, Lawrence J, Gates C, et al. Adjacent segment disease after cervical spine fusion. *Instr Course Lect* 2009; 58: 747.
- Kwon B, Katz JN, Kim DH, et al. A review of the 2001 Volvo Award winner in clinical studies: Lumbar fusion versus nonsurgical treatment for chronic low back pain: A multicenter randomized controlled trial from the Swedish lumbar spine study group. *Spine* 2006; 31: 245.
- Huskisson EC. Measurement of pain. *Lancet* 1974; 2: 1127.
- Fritzell P, Hagg O, Wessberg P, et al. 2001 Volvo Award Winner in Clinical Studies: Lumbar fusion versus nonsurgical treatment for chronic low back pain: A multicenter randomized controlled trial from the Swedish Lumbar Spine Study Group. *Spine* 2001; 26: 2521.
- Brox JI, Reikeras O, Nygaard O, et al. Lumbar instrumented fusion compared with cognitive intervention and exercises in patients with chronic back pain after previous surgery for disc herniation: A prospective randomized controlled study. *Pain* 2006; 122: 145.
- Brox JI, Sorensen R, Friis A, et al. Randomized clinical trial of lumbar instrumented fusion and cognitive intervention and exercises in patients with chronic low back pain and disc degeneration. *Spine* 2003; 28: 1913.
- Fairbank J, Frost H, Wilson-MacDonald J, et al. Randomised controlled trial to compare surgical stabilisation of the lumbar spine with an intensive rehabilitation programme for patients with chronic low back pain: The MRC spine stabilisation trial. *BMJ* 2005; 330: 1233.
- Guyer RD, McAfee PC, Banco RJ, et al. Prospective, randomized, multicenter Food and Drug Administration investigational device exemption study of lumbar total disc replacement with the CHARITE artificial disc versus lumbar fusion: Five-year follow-up. *Spine J* 2009; 9: 374.
- Hohaus C, Ganey TM, Minkus Y, et al. Cell transplantation in lumbar spine disc degeneration disease. *Eur Spine J* 2008; 17(suppl 4): 492.
- Siepe CJ, Tepass A, Hitzl W, et al. Dynamics of improvement following total lumbar disc replacement: Is the outcome predictable? *Spine* 2009; 34: 2579.
- Fassett DR, Kurd MF, Vaccaro AR. Biologic solutions for degenerative disk disease. *J Spinal Disord Tech* 2009; 22: 297.
- Le Maitre CL, Baird P, Freemont AJ, et al. An in vitro study investigating the survival and phenotype of mesenchymal stem cells following injection into nucleus pulposus tissue. *Arthritis Res Ther* 2009; 11: R20.
- Vadala G, Studer RK, Sowa G, et al. Coculture of bone marrow mesenchymal stem cells and nucleus pulposus cells modulate gene expression profile without cell fusion. *Spine* 2008; 33: 870.
- Watanabe T, Sakai D, Yamamoto Y, et al. Human nucleus pulposus cells significantly enhanced biological properties in a coculture system with direct cell-to-cell contact with autologous mesenchymal stem cells. *J Orthop Res* 2009; 28: 623.
- Yang SH, Wu CC, Shih TT, et al. In vitro study on interaction between human nucleus pulposus cells and mesenchymal stem cells through paracrine stimulation. *Spine* 2008; 33: 1951.
- Risbud MV, Albert TJ, Guttapalli A, et al. Differentiation of mesenchymal stem cells towards a nucleus pulposus-like phenotype in vitro: Implications for cell-based transplantation therapy. *Spine* 2004; 29: 2627.
- Yang H, Wu J, Liu J, et al. Transplanted mesenchymal stem cells with pure fibrinogen gelatin-transforming growth factor-beta1 decrease rabbit intervertebral disc degeneration. *Spine J* 2010; 10: 802.
- Blanco JF, Graciani IF, Sanchez-Guijo FM, et al. Isolation and characterization of mesenchymal stromal cells from human degenerated nucleus pulposus: Comparison with bone marrow mesenchymal stromal cells from the same subjects. *Spine* 2010; 35: 2259.
- Hiyama A, Mochida J, Iwashina T, et al. Transplantation of mesenchymal stem cells in a canine disc degeneration model. *J Orthop Res* 2008; 26: 589.
- Henriksson HB, Svanvik T, Jonsson M, et al. Transplantation of human mesenchymal stems cells into intervertebral discs in a xenogeneic porcine model. *Spine* 2009; 34: 141.
- Sakai D, Mochida J, Iwashina T, et al. Differentiation of mesenchymal stem cells transplanted to a rabbit degenerative disc model: Potential and limitations for stem cell therapy in disc regeneration. *Spine* 2005; 30: 2379.
- Sakai D, Mochida J, Iwashina T, et al. Regenerative effects of transplanting mesenchymal stem cells embedded in atelocollagen to the degenerated intervertebral disc. *Biomaterials* 2006; 27: 335.

26. Haufe SM, Mork AR. Intradiscal injection of hematopoietic stem cells in an attempt to rejuvenate the intervertebral discs. *Stem Cells Dev* 2006; 15: 136.
27. Dominici M, Le Blanc K, Mueller I, et al. Minimal criteria for defining multipotent mesenchymal stromal cells. The International Society for Cellular Therapy position statement. *Cytotherapy* 2006; 8: 315.
28. Bernardo ME, Locatelli F, Fibbe WE. Mesenchymal stromal cells. *Ann NY Acad Sci* 2009; 1176: 101.
29. Ruan D, He Q, Ding Y, et al. Intervertebral disc transplantation in the treatment of degenerative spine disease: A preliminary study. *Lancet* 2007; 369: 993.
30. Adams MA, Dolan P, Hutton WC. The stages of disc degeneration as revealed by discograms. *J Bone Joint Surg Br* 1986; 68: 36.
31. Modic MT, Ross JS. Lumbar degenerative disk disease. *Radiology* 2007; 245: 43.
32. Davidson M, Keating JL. A comparison of five low back disability questionnaires: Reliability and responsiveness. *Phys Ther* 2002; 82: 8.
33. Watanabe A, Benneker LM, Boesch C, et al. Classification of intervertebral disk degeneration with axial T2 mapping. *AJR Am J Roentgenol* 2007; 189: 936.

Contacting the Editorial Office

To reach the *Transplantation* Editorial Office, please use the following contact information:

North American Editorial Office

Manikkam Suthanthiran, MD, Editor

Transplantation

New York-Presbyterian Hospital

Weill Medical College of Cornell University

525 East 68th Street, Box 310

New York, NY 10021, USA

Phone: 1-212-746-4422

Fax: 1-212-746-6894

E-mail: txpl@med.cornell.edu

European Editorial Office

Professor Kathryn J. Wood, Editor

Transplantation

Nuffield Department of Surgery

University of Oxford

John Radcliffe Hospital

Headington, Oxford OX3 9DU, UK

Phone: 44 1865-221310

Fax: 44 1865-763545

E-mail: transplantation@nds.ox.ac.uk